

## Research Article

# Identification by Light Microscopy of *Blastocystis* Sp. in Oysters *Crassostrea Virginica*

Ignacio Martínez-Barbabosa<sup>1,2</sup>, Manuel Gutiérrez Quiróz<sup>1</sup>, Leticia Ruiz González<sup>1</sup>, Adela Luisa Ruiz Hernández<sup>1</sup>

<sup>1</sup>Departamento de Microbiología y Parasitología. Facultad de Medicina. Universidad Nacional Autónoma de México. Avenida Universidad 3000 Ciudad Universitaria, Del. Coyoacán. Ciudad de México. 04510 México.

<sup>2</sup>Departamento de Atención a la Salud. Área de Ciencias Básicas. Laboratorio de Parasitología Humana. Universidad Autónoma de Metropolitana-Xochimilco. Calzada del Hueso 1100. Col. Villa Quietud. Del. Coyoacán. Ciudad de México. C.P. 04960. México.

\*Correspondence to: I. Martínez-Barbabosa. Departamento de Atención a la Salud. Laboratorio de Parasitología Médica. Universidad Autónoma Metropolitana-Xochimilco. Calzada del Hueso 1100. Colonia Villa Quietud, Del. Coyoacán C.P. 04960. México City; Tel: +52 5483-7558. Fax: +52 5483-7218 ; E-mail: imarti@correo.xoc.uam.mx

Received: November 22, 2017; Accepted: December 06, 2017; Published: December 12, 2017;

## Abstract

*Blastocystis* sp., is an anaerobic unicellular microorganism frequently found in the gastrointestinal tract of humans and of a wide gamma species of vertebrate and invertebrate animals. However, its presence in oysters has not been reported, and if the consumption of oysters infected with *Blastocystis* sp. it is a way of acquiring the infection for humans. The objective of this study was to determine by light microscopic analysis the presence of *Blastocystis* sp in oysters *Crassostrea virginica* (*C. virginica*) sold for human consumption in markets in Mexico City. 500 oysters were obtained. The intestine of each oyster was dissected and the faecal material was examined. The faeces were examined by light microscopic. 77% were infected with cysts of *Blastocystis* sp. Eaten raw, these oysters are a possibility source of infection for humans.

**Key words:** *C. virginica*, oyster, *Blastocystis hominis*, *Blastocystis* sp.

## Introduction

*Blastocystis* sp. is a single-celled, genetically heterogeneous protist, phylogenetically placed within the Stramenopiles a common inhabitant of the human intestinal tract [1]. It is also found in a diverse array of the other vertebrates including pigs, cow, chickens, and reptiles and has a worldwide distribution, highlighting both its low host specific and zoonotic potential. The parasitization by *Blastocystis* is considered a zoonosis with fecal-oral transmission route. [2-4].

*Blastocystis* sp. is probably the most common intestinal protozoan detected in human faecal samples worldwide. The infection occurs in immunocompetent and immunosuppressed individuals [5-7]. The prevalence of *Blastocystis* sp. in humans, it can be higher than 5% in developed countries and as high as 76% in developing countries [8]. In Mexico, young children with low weight showed a prevalence of 80% [9]. Transmission is fecal-oral, as is the case with other intestinal protozoa. The man acquires the infection especially of food and water contaminated with cysts of *Blastocystis* sp. coming from a carrier. [10-12]

*Blastocystis* sp. They multiply asexually by binary fission, endodiogenesis, schizogony, and plasmotomy. They are spherical cells, commonly presents four different morphological forms: vacuolated form, granular form, amoeboid form and cyst form. The vacuolated form is of variable size measuring from 5 to 30µ it has a

large central vacuole that occupies 50 to 95% of the cell surrounded by a peripheral band of the cytoplasm with several nuclei and numerous mitochondria. It is the predominant form in the gastrointestinal tract. The amoeboid form presents pseudopodia and has great phagocytic activity. The granular form has a large amount of mitochondria that give it a granular appearance [6]. The diagnosis is made with the usual coprologic studies; the most usual is the direct examination in fresh in preparations stained with lugol that allows to identify mainly the cystic form.

The epidemiology of *Blastocystis* sp. it is still enigmatic and controversial in some aspects. The transmission is done by fecal-oral route, similar to what happens with other intestinal protozoa transmitted by fecalism. However, the consumption of live animals infected with *Blastocystis* sp. It has not yet been determined as a way of transmitting the microorganism to humans. In a previous study oriented to the search of parasites in oyster different species of oysters, we observed several cells morphologically similar to cysts of *Blastocystis* sp. Find that motivated the realization of the present investigation.

## Objective

Identify, by light microscopy, cellular forms similar to *Blastocystis* sp. in oysters' *C. virginica*.

## Material and methods

### Study design

In the first semester of 2017, a cross-section descriptive sampling was carried out in order to detect cells morphological similar a *Blastocystis* sp. *C. virginica* oysters collected in Mexico City.

### Study area

Mexico City that has 8,851,080 inhabitants and is located at parallels 19° 36' and 19° 03' north of the equator, and at 98° 57' and 99° 22' west of the Greenwich Meridian, at an altitude 2,240 meters (7,350 ft), with humid temperate climate and average annual temperature 16° C. The city consists of 16 administrative delegations distributed on the territory of 1,485 square kilometers (573 sq mi) [13].

### Collection of specimens

500 oysters of the genus *C. virginica* from the Gulf of Mexico were collected in different markets of Mexico City. All the samples were carefully washed with individual brushes and sterile distilled water before being opened. Subsequently, each oyster was placed individually in a sterile Petri dish to identify and dissect the intestine. Next, the intestinal contents were extracted.

### Microscopic identification of *Blastocystis* sp.

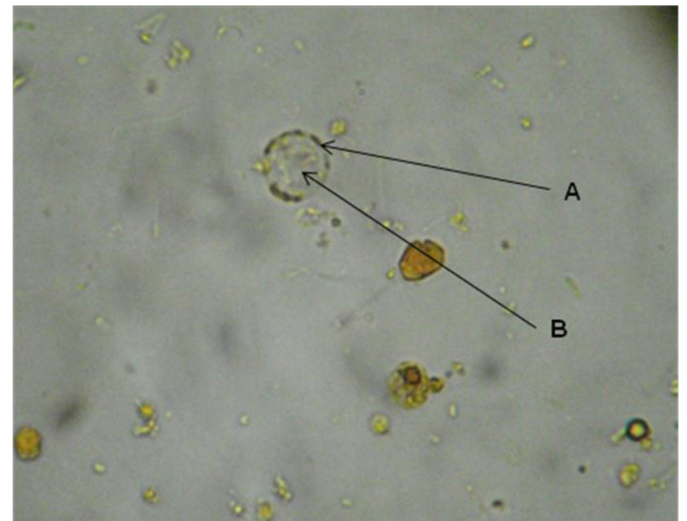
Two smears were made with the intestinal content of each oyster on two different slides. In one case analysis was carried out by direct examination of faeces using a sterile saline isotonic solution at 0.85% and stained with lugol. The other was stained with Gomori trichrome for detailed identification of the morphology of *Blastocystis* [14]. The identification of *Blastocystis* was performed on a Carl Zeiss microscope at 100 and 400x and cell counts for each microscopic field were taken.

## Results

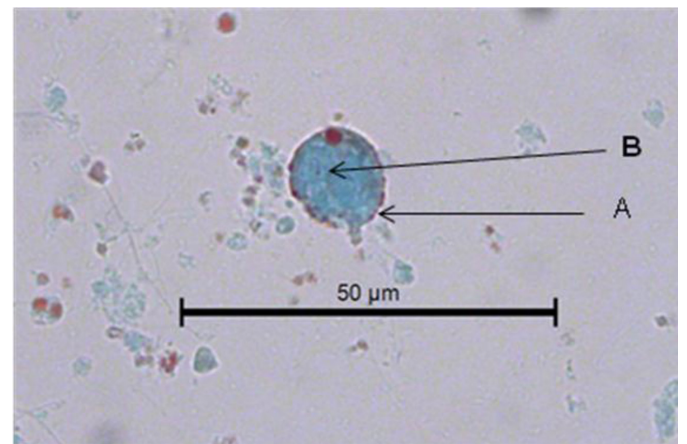
Morphological Identification of *Blastocystis* sp was carried out using a Carl Zeiss microscope light at 100 and 400x. Of the 500 *C. virginica* oysters analyzed by microscopic identification, 77% were infected with cysts of *Blastocystis* sp.

The cystic form was observed. Within, granules with more stain were seen in some discontinuous zones on the periphery and also fixed to the circumference as a thin membrane in discontinuous areas. The central body, of rather indefinite form, displaced the cytoplasm (Figure 1).

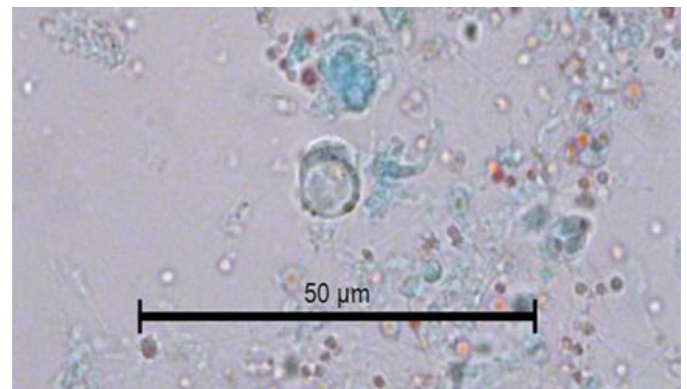
In Figure 2, another cyst of *Blastocystis* sp. can be seen stained with Gomori isolated from fresh faeces. It is clearer than the previous one stained with lugol. The peripheral granules, of which one is of notable size, are seen more clearly. The central body is more clearly defined. The Gomori staining also permits the observer to see a large central vacuole that occupies more than 70% of the cytoplasm. Furthermore, it compresses the cytoplasm to the cell periphery. Its size can be calculated as 7 µm. The vacuolar morphology of *Blastocystis* can be clearly appreciated in Figure 3.



**Figure 1.** *Blastocystis* sp. cyst in the faeces of *C. virginica* stained with lugol. A. Peripheral granules. B. Central body.



**Figure 2.** Image of a *Blastocystis* sp. cyst in the faeces of *C. virginica* stained with Gomori. A. Peripheral granules. B. Central body.



**Figure 3.** Image of the vacuolar form of *Blastocystis* sp. in the faeces of *C. virginica* stained with Gomori.

## Discussion

Worldwide, the production, export and consumption of seafood represents a very high source of economic income in different countries. In Mexico, oyster exploitation is one of the most important fishing activities. The Gulf of Mexico generates 90% of the national oyster production. It occupies the fourth place in the production of oysters in Latin America [15]. The American Oyster *C. virginica* is one of the members of the Family Ostreidae of greater commercial importance. The oyster is grown from the Gulf of San Lorenzo in Canada to the Laguna de Términos in the state of Campeche, Mexico.

In Mexico City, the oyster *C. virginica* cultivated mainly in the coastal lagoons of the states of Tabasco and Veracruz is consumed. In this area, the semi-cultivation of *C. virginica* native to the Gulf of Mexico is carried out through collection of wild seed and aquaculture-fishing management in natural banks. The production of the oyster in the state of Tabasco takes place in the lagoon systems in the municipalities of Cardenas and Mecoatan. In the state of Veracruz, *C. virginica* is cultivated in the Tamiahua lagoon, considered as an important oyster reserve of America, located between the coordinates 21° 06' and 22° 05' of North latitude and the 97° 23' and 97° 46' in length; it produces 400 thousand tons annually. A large part of this production is exported to different countries [16].

The raw consumption of raw oysters infected with *Blastocystis* sp. it implies a potential risk of zoonotic infection and consequently of developing blastocystosis [17, 18]. Intestinal disease characterized by severe diarrhea, the symptoms attributable to *B. hominis* include: diarrhea, abdominal pain, nausea, vomiting, flatulence, fatigue, anorexia, leading to dehydration and significant weight loss. Generally, fecal leukocytes are not found and in some cases eosinophilia and chronic urticaria have been observed. In immunosuppressed people the symptoms can be progressive; there is a greater tendency to chronicity [19, 20].

From the epidemiological point of view, the consumption of raw oysters infected with *Blastocystis* sp. it represents a risk for the consumer, due to its great ability to adapt to the ecological conditions of the environment in which they live, they could adapt to the physiological conditions provided by the human intestine, and in this way get to reproduce in it becoming a reservoir and source of infection to acquire the disease. This is the first report in which he mentions *C. virginica* as a reservoir of *Blastocystis* sp. in oysters grown in the Mexican Republic.

In conclusion, a high prevalence of infection by *Blastocystis* sp. was determined, in the oyster *C. virginica* the cyst was the predominant form in the oysters examined. The consumption of raw oysters infected with *Blastocystis* sp. represents a potential risk for the consumer of acquiring blastocystosis. Risk in which the most susceptible population is the undernourished and that with some type of immunodeficiency.

## References

1. Silberman JD, Sogin ML, Leipe DD, Clark CG (1996) Human parasite finds taxonomic home. *Nature* 380: 398. [crossref]

2. Scanlan PD (2012) Blastocystis: past pitfalls and future perspectives. *Trends Parasitol* 28: 327–334. [crossref]
3. Santín M, Gómez-Muñoz Mt, Solano-Aquilar G, Fayer R. Development of a new PCR protocol to detect and subtype *Blastocystis* spp. from humans and animals. *Parasitol Res* 109: 205–12
4. Parija SC, Jeremiah S (2013) Blastocystis: Taxonomy, biology and virulence. *Trop Parasitol* 3: 17–25. [crossref]
5. Clark CG, van der Giezen M, Alfellani MA, Stensvold CR (2013) Recent developments in Blastocystis research. *Adv Parasitol* 82: 1–32. [crossref]
6. Stensvold CR, Suresh GK, Tan KS, Thompson RC, Traub RJ, et al. (2007) Terminology for Blastocystis subtypes--a consensus. *Trends Parasitol* 23: 93–96. [crossref]
7. Yoshikawa H, Koyama Y, Tsuchiya E, Takami K (2016) Blastocystis phylogeny among various isolates from humans to insects. *Parasitol Int* 65: 750–759.
8. Tueki H, Hamed Y, Heidari-Hengami M, Najafi-Asl M, Rafati S, Sharifi- Sarasiabi (2017) Prevalence of intestinal parasitic infection among primary school children in southern Iran. *J Parasitol Dis* 41: 659–665.
9. Martínez-Barbabosa I, Gutiérrez-Quiroz M, Ruiz-González L, Ruiz-Hernández AL, Gutiérrez-Cárdenas EM (2010) Blastocystis hominis y su relación con el estado nutricional de escolares en una comunidad de la sierra de Huayacocotla, Veracruz, México. *Rev Biomed* 21: 77–84.
10. Kaya S, Cetin ES, AridoAYan BC, Arikani S, Demirci M (2007) Pathogenicity of Blastocystis hominis, a clinical reevaluation. *Turkiye Parazitolo Derg* 31: 184–187. [crossref]
11. Lee LI, Chye TT, Karmacharya BM, Govind SK (2012) Blastocystis sp.: waterborne zoonotic organism, a possibility? *Parasit Vectors* 5: 130. [crossref]
12. Batista L, Pérez Jove J, Rosinach M, Gonzalo V, Sainz E, et al. (2017) Low efficacy of metronidazole in the eradication of Blastocystis hominis in symptomatic patients; case series and systematic literature review. *Gastroenterol Hepatol* 40: 381–387.
13. INEGI (2015) Instituto Nacional de Geografía Estadística e Informática Centro de Población y Vivienda.
14. Sheenan DJ, Raucher BG, McKittrick JC (1986) Association of Blastocystis hominis with signs and symptoms of human disease. *J Clin Microbiol* 24: 548–550.
15. Maeda-Martínez, AN (2008) Estado actual del cultivo de bivalvos en México. In: Lovatelli A, Fariás A, Uriarte I. (ed.), Taller Regional de la FAO sobre el Estado actual del cultivo y manejo de moluscos bivalvos y su proyección futura: factores que afectan su sustentabilidad en América Latina. Actas de Pesca de la FAO, No. 12, Roma 91–100.
16. Contreras EF, Castañeda LO (2000) Las lagunas costeras y estuarios del Golfo de México: hacia el establecimiento de índices ecológicos. En: Diagnóstico ambiental del Golfo de México. INE-SEMANAT. México D.F.
17. Parkar U, Traub RJ, Kumar S, Mungthin M, Vitali S, et al. (2007) Thompson RC. Direct characterization of Blastocystis from faeces by PCR and evidence of zoonotic potential. *Parasitology* 134: 359–367.
18. Poirier P, Wawrzyniak I, Vivarès CP, Delbac F, El Alaoui H (2012) New insights into Blastocystis spp.: a potential link with irritable bowel syndrome. *PLoS Pathog* 8: e1002545. [crossref]
19. Toro MEM, Vichido LMA; Montijo BE, Cervantes BR, Zárate MF, et al. (2017) Blastocystis hominis and Chronic Abdominal Pain in Children: Is there an Association between Them? *J Trop Pediatr*
20. Mauss J, Retz M, Dilts R, Langland J (2017) Multiple sampling and SAF-Fixative Triple-Faeces Testing for Dysbiosis and Pathogenic Infections of the Gastrointestinal Tract: Case Report. *Altern Ther health Med*.

## Citation:

Ignacio Martínez-Barbabosa, Manuel Gutiérrez Quiroz, Leticia Araceli Ruiz González, Adela Luisa Ruiz Hernández (2017) Identification by Light Microscopy of *Blastocystis* Sp. in Oysters *Crassostrea Virginica*. *Integr J Vet Biosci* Volume 1(2): 1–3